

ORIGINAL PAPERS

Multidisciplinary approach and multimodal therapy in resected pancreatic cancer. Observational study

R. Morales¹, A. Cuadrado¹, J. F. Noguera¹, C. Dolz², A. Vilella², J. Riera², M. González de Cabo³, A. Arrivi⁴, E. Falcó⁴, M. García Bonafe⁵, M. Company⁵, J. C. Vicens¹ and A. Socías⁶

¹Dpt. of Surgery. ²Dpt. of Gastroenterology. ³Dpt. of Radiology. ⁴Dpt. Oncology. ⁵Dpt Pathology. ⁶Dpt of Intensive Care. Hospital Son Llàtzer. Palma de Mallorca, Spain

ABSTRACT

Objective: analysis and evaluation of a multidisciplinary approach, postoperative results and survival of a group of patients with resected pancreatic cancer after a multimodal therapy.

Design: descriptive, prospective and observational study.

Patients: between January 2004 and December 2004, 124 patients with pancreatic cancer were evaluated. In 30 patients pancreatic resection was performed, and they are the object of this study. Results of preoperative evaluation, postoperative morbidity and mortality, and long term survival were studied.

Results: diagnostic evaluation was completed in ambulatory basis in 20% of the patients. In 63% of cases, admission was done in the same day of surgery. In 3 patients (9%), tumor resection was not achieved, therefore, concordance between radiological and surgical resectability rate was 91%. Resectability rate was 24.1%. Surgical Mortality was 3.3%, with a global morbidity rate of 56.6%. Survival at one, two, three and, four years was 76.2%, 56.3%, 43%, y 27.3% respectively.

Conclusions: technological development and coordination of efforts in multidisciplinary teams offer an accurate evaluation of tumor involvement, and may reduce the number of laparotomies without tumor resection. The application of a systematic and generalized multimodal treatment in pancreatic cancer is progressively showing a tendency of progressive increase in resectability and survival rates in pancreatic cancer.

Key Words: Pancreatic cancer. Multidisciplinary. Multimodal Therapy.

INTRODUCTION

Pancreatic Cancer (PC) has increased its incidence in Spain over 160% from 1980 to 2005 (1,2). Its poor prognosis has generated a traditional pessimism. However, in

recent years a renewed interest has emerged thanks to the multidisciplinary approach which is resulting in a better tumor extension evaluation, standardization of the surgical technique, oncologic adjuvant protocols, and more recently, neoadjuvant therapy (3,4). These developments, together with reduction of surgical morbidity and mortality, the appearance of increasingly effective cytostatics, and the implementation of multimodal systematic therapy in the majority of patients, are achieving for the first time, an increase of long term survival in pancreatic cancer (5-7).

OBJECTIVES

Evaluation of tumor extension with a multidisciplinary approach. 2. Analysis of postoperative results and survival, after the implementation of a multimodal therapy, in a group of consecutive patients with resected pancreatic malignancies. Variables studied: rate of tumor extension evaluation in ambulatory basis, surgical resectability rate, mortality and postoperative morbidity, peroperative transfusion rate, reoperation, hospital stay, readmission, histological findings and survival.

PATIENTS AND METHODS

Patients selection

Between January 2004 and December 2009, 124 patients with pancreatic cancer were analyzed prospectively at the

Received: 05-02-10.
Accepted: 30-06-10.

Correspondence: R. Morales Soriano. Servicio de Cirugía General y Digestivo. Hospital Son Llàtzer. 07198 Palma de Mallorca. e-mail: rafa.morales@telefonica.es; rmorales@hsl.es

R. Morales, A. Cuadrado, J. F. Noguera, C. Dolz, A. Vilella, J. Riera, M. González de Cabo, A. Arrivi, E. Falcó, M. García Bonafe, M. Company, J. C. Vicens, A. Socías. Multidisciplinary Approach and Multimodal Therapy in resected Pancreatic Cancer. Observational Study. *Rev Esp Enferm Dig* 2011; 103: 5-12.

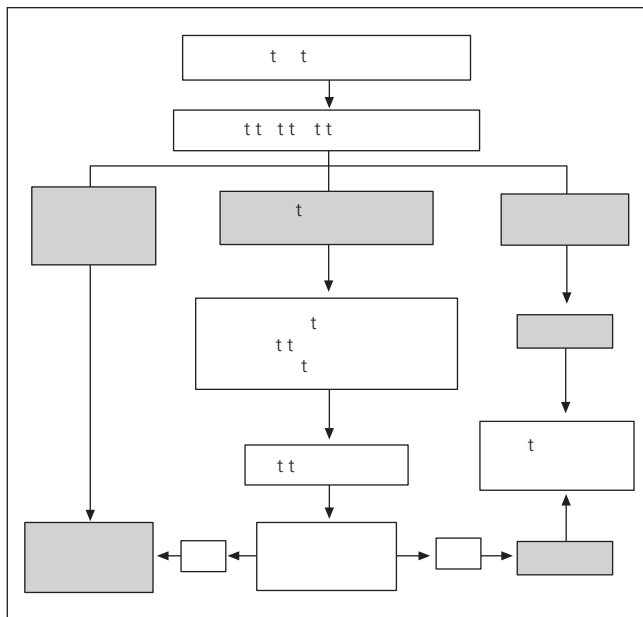


Fig. 1. Algorithm guideline approved by the Hepatobiliary pancreatic Tumor Committee

Hospital Son Llàtzer. Pancreatic resection was performed in 30 patients, who are the object of this study. Inclusion criteria: Patients with malignant pancreatic tumours that underwent resection. Exclusion Criteria: Patients with cholangiocarcinoma, ampullary adenocarcinoma/periapillary, non-invasive mucinous neoplasms, and malignant tumours of the duodenum were excluded. All patients were assessed at the weekly meeting of Liver-Tumor Committee, composed by surgeons, gastroenterologists, radiologists, oncologists and pathologists. A guideline protocol previously agreed and approved by the committee was applied to all patients. All patients signed a specific informed consent for evaluation and treatment procedures.

Extension and resectability study

The study began with a double-contrast CT scan with oral and intravenous dye, three phases, and fine cuts (1-2 mm). In 26 patients a EUS was done, of which, a fine needle aspiration was made in 22 cases. Until 2006, cytological diagnosis was made with conventional Papanicolaou staining from samples obtained by biliary brushing with retrograde cholangiopancreatography (ERCP) and FNA (fine needle aspiration) endoscopic ultrasonography (EUS). From 2006 on, a liquid cytology technique (Thin-Prep®) was introduced, with Diff-Quick staining to assess the adequacy of cellularity. ERCP was performed with placement of a plastic biliary stent (8 fr.) in patients with severe jaundice, or surgical intervention exceeding one week, as well as in patients included in the preoperative neoadjuvant protocol. Percutaneous transhepatic drainage

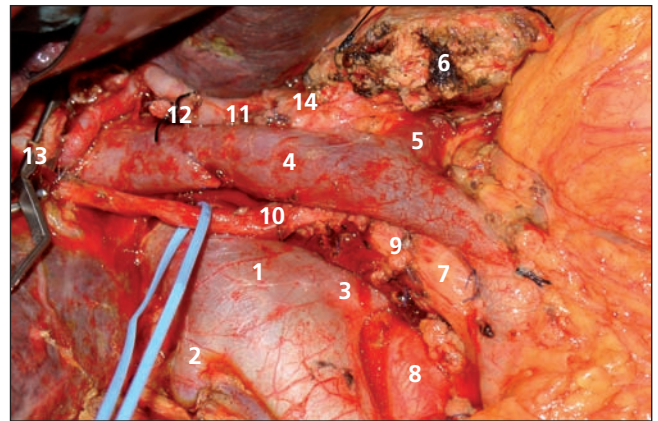


Fig. 2. Surgical field after cephalic duodenopancreatectomy. 1. V. Cava; 2. Right Renal vein; 3. Left renal vein; 4. Portal vein; 5. Splenic vein; 6. Distal pancreas; 7. Superior mesenteric artery; 8. Aorta; 9. Superior duodenopancreatic artery; 10. Right Hepatic artery coming from the superior mesenteric artery; 11. Common hepatic artery; 12. Ligated gastroduodenal artery; 13. Common bile duct (sectioned); 14. Celiac Trunk.

was done when the endoscopic route failed. The guideline protocol applied is showed in Fig. 1. Patients were classified in three groups: 1. Metastatic disease, with radiologic evidence of liver, lung or peritoneal metastases. 2. Resectable disease: resectable tumours without vascular infiltration, and 3. Locally advanced disease: tumours with infiltration of portal, or superior mesenteric vein. In this last group, a preoperative neoadjuvant protocol with gemcitabine (1000 mg/m²) and oxaliplatin (100 mg/m²) was performed during 4 cycles, together with a posterior re-evaluation with CT scan. In patients without systemic progression surgery was scheduled 4 weeks after the last cycle. Tumours with arterial involvement (common hepatic artery, celiac axis or superior mesenteric artery) were considered unresectable.

Surgical resection limits

Pancreaticoduodenectomy included an antrectomy. Dissection of uncinate process reached the right border of the superior mesenteric artery (5,8,9). Lymphadenectomy included the hepatoduodenal ligament, celiac trunk and infraduodenal interaortocaval space (Fig. 2).

Histological analysis

An intraoperative and definitive study of resection margins was performed at 3 levels: 1. Hepatic duct margin, 2. Pancreatic section margin, and 3. Superior mesenteric artery margin. Involvement of resection margins was defined according to the American Joint Commission on Cancer Staging Manual (6th Edition). R0: Absence of tumor cells in all resection margins, R1: presence of tu-

mor cells in any of the margins, and R2: presence of macroscopic tumor in any margin.

Patient follow-up and survival. After surgery, patients received adjuvant therapy with (gemcitabine 1000 mg/m²) and a follow-up every 3 months with analysis, tumor markers (CEA and CA 19-9) and CT. For patients without recurrence after 3 years, the interval between checks was extended to 6 months for patients living outside our Health Area, follow-up was performed by telephone. For survival analysis, patients with follow up less than twelve months were excluded. The patient died in the immediate postoperative was excluded for long term survival analysis.

Definitions

—*Pancreatic Fistula.* Drainage of more than 50 ml of liquid with amylase superior to three times the normal limit of plasmatic amylase during ten or more days, or radiologic or surgical evidence of anastomotic dehiscence.

—*Slow gastric emptying.* Unable to start oral diet, or requirement of a nasogastric tube during more than ten days postoperatively.

—*Surgical Mortality.* Death within 30 days after surgery or anytime during hospitalization.

Statistical analysis

Descriptive analysis of quantitative variables is expressed through the average, standard deviation, median and ranges. Qualitative variables are expressed in percentages. Comparisons between both were made with Chi-square, and exact Fischer's test. A level of statistical significance $p < 0.05$ was established. Survival analysis was done using the Kaplan-Meier test.

RESULTS

Preoperative evaluation

Between January 2004 and December 2009, pancreatic cancer was diagnosed to 124 patients at the Hospital Son Llàtzer. Thirty of these patients underwent tumor resection (surgical resectability 24.1%). Initial symptoms were jaundice (73.5%, 22 patients), epigastric pain (16.6%, 5 patients), acute pancreatitis (6.6%, 2 patients), and toxic syndrome (3.3%, 1 patient). The average age was 65.2 years (37-85 years). There were 16 male (53.4%), and 14 women (46.6%). From the 33 patients who were considered resectable, tumor resection could not be performed in 3 cases (9%), because of subcentimetric hepatic metastasis (2 cases), and arterial and venous vascular invasion (1 case), therefore correlation between radiological and surgical resectability was 90.9%. Tumor was visible by

CT-scan in 93.3% of patients. EUS was done in 26 patients (86.7%), with tumor identification in 25 cases (diagnostic accuracy: 96.1). In the 2 patients where tumor was not visible with CT, diagnosis was made with EUS, and cytological confirmation of malignancy was made by endosonographic puncture. Preoperative biliary drainage was performed in 15 patients (52%), using endoscopic route in 11 cases and percutaneous transhepatic drainage in 4 cases. We could not find significant differences in local or systemic infections between patients with biliary stent (4 patients), and patients without (2 patients) ($p = 0.07$). Tumor extension evaluation could be done on an outpatient basis in 20% of patients (6 cases), and admission was performed the same day of surgery in 19 cases (63%).

Surgical results

Of the 120 patients with a PC diagnosis, pancreatic resection was performed on 30 (surgical resectability rate: 24.1%). Three laparotomies without tumour resection were done (9%). Techniques applied were Whipple pancreaticoduodenectomy (25 cases, 83.4%), distal pancreatectomy with splenectomy (4 cases, 13.3%), and total pancreatectomy with splenectomy (1 case). In four patients (12%), neighbour organs were resected because of local invasion (subtotal gastrectomy 2 cases, partial colectomy 1 case, and hepatic segmentectomy 1 case). Hepatic resection was performed due to an isolated hepatic metastasis in an asymptomatic patient after two years of neoadjuvant therapy and radiologic disappearance of the tumour. Portal vein resection was performed in 3 patients because of tumor invasion (2 lateral resections with primary suture, and 1 segmentary resection with polytetrafluoroethylene (PTFE) graft reconstruction.

Transfusion rate was 14% for patients with preoperative haemoglobin superior to 12 gr/dl and 38% for those patients < 12 g/dl. Mortality in the series was 3.3% (one patient died with acute portal vein thrombosis after portal segmentary resection). Global morbidity was 56.6%. Reintervention rate was 6.6% (one postoperative intestinal obstruction, and one intra-abdominal extravasation of jejunostomy catheter). Readmission rate was 6.6% (2 cases): one adhesive intestinal obstruction one month after surgery, and one intra-abdominal collection 15 days after surgery which resolved spontaneously. Medical complications rate was 29.5%: two central track infections, one subclavian vein thrombosis, one urinary infection and one cardiac arrhythmia which required a pace-maker placement. Perioperative results are shown in Table I.

Histological results

Resection margins were clear (R0) in 24 cases (80.1%), R1 in 4 cases (13.3%), and R2 in 2 patients (6.6%). The

Table I. Perioperative Results

Perioperative Results	n (%)
Mortality	1 (3.3%)
General morbidity	56.6%
Medical Complications	5 (29.5%)
Surgical Complications	12 (70.5%)
– Slow Gastric Emptying	2 (6.6%)
– Pancreatic Fistula	2 (6.6%)
– Intra-abdominal Abscess	2 (6.6%)
– Postoperative Haemorrhage	1 (3.3%)
– Chylous Ascites	1 (3.3%)
– Wound Infection	1 (3.3%)
– Enteral Catheter Extravasation	1 (3.3%)
– Biliary Fistula	1 (3.3%)
– Intestinal Obstruction	1 (3.3%)
Reinterventions	2 (6,6%)
Postoperative Intestinal Obstruction	
Jejunostomy Catheter Extravasation	
Readmissions	2 (6,6%)
Adhesive Intestinal Obstruction	
Postoperative Abscess	
Operative Duration	Average: 6,3 (4-9) hours Median: 6,5 hours
Postoperative Stay	15,6 days (7-42 days)

Table II. Histologic results

Histology	
Ductal Adenocarcinoma	23
Invasive Intraductal Papillary Mucinous	2
Acinar Adenocarcinoma	1
Carcinoma Endocrino	1
Adenocarcinoma Mixto (Pancreático-Biliar)	1
Sarcomatoid Carcinoma	1
Invasive Solid Pseudopapilar Tumor	1
Cellular Differentiation	
G1	31%
G2	55%
G3	7%
G4	7%
T N M	
T1 – T2 – T3 – T4	0 – 16,6% - 80,1% - 3,3%
N0 – N1	23,3% - 76,7%
Nodes per patient Average	18,5 (5-53)
Resection margins	
R0	80,1%
R1	13,3%
R2	6,6%
Tumor size	3,9 cm (1,5 - 17)

average of isolated nodes per patient was 18.5 (median 15). Perineural invasion was confirmed in 27 of 30 patients (90%). The three patients without perineural invasion corresponded to one endocrine carcinoma, an invasive intraductal papillary mucinous carcinoma, and invasive solid pseudopapillary tumor respectively. Lymph node involvement was present in 76.7% of patients. The average of examined lymph nodes per patient was 18.5 (Table II).

Follow up and Survival

Adjuvant chemotherapy was administered in 82.8% (25 patients). In three patients chemotherapy was not administered, in one patient ought to advanced age, and in two cases ought to the histology of the tumor (solid pseudopapillary tumor in one case, and neuroendocrine carcinoma in another case). Postoperative radiotherapy was applied in 17% of patients (3 cases with involvement of the resection margins, and two cases of local recurrence). Preoperative neoadjuvant therapy was performed on 5 patients. Postoperative follow-up was completed in all patients except for one, due to unnoticed residence change. Twelve patients died during follow up. Causes of death were tumor progression (8 cases), acute myocardial (1 case), mesenteric ischemia (1 case), pulmonary embolism (1 case), and development of prostate adenocarcinoma with pulmonary metastases in another case. Four patients had suffered or developed a malignancy other than CP (two patients with complete remission from lym-

phoma, and one patient diagnosed during follow-up of a prostate adenocarcinoma). In the fourth patient, one gastrointestinal stromal tumors in stomach and proximal jejunum was diagnosed during pancreatectomy being both resected during surgery. Follow up average was 24.6 months (4-68 months), with median of 15 months. Even though a greater survival rate is described for some pancreatic malignancies such as intraductal papillary carcinoma or endocrine carcinoma if compared to ductal adenocarcinoma, all cases described in the series presented criteria of malignancy and have therefore been included in the survival evaluation. The current median survival was 24 months (median 14). Survival at one, two, three and four years was 76.2%, 56.3%, 43% and 27.3% respectively. Average survival decreases to 20.7 months (median 13) if malignancies with better prognosis described above are excluded. Average survival of patients without nodes invasion was significantly greater to that of patients with invaded nodes (N0: average 44.8 months, median 50; N1: average 16.3 months, median 14) ($p = 0.0211$). Survival rate presented no differences between patients without resection margins invasion (average 22 months) and patients with resection margins invasion (average 20.8) ($p = 0.3536$).

DISCUSSION

Pancreatic cancer incidence has increased in Spain over a 160% between 1980 and 2005, with 4.591 deaths registered in 2005 (1,2). PC is considered to be the digestive tumor with worse prognosis due to its early dissemination,

late diagnosis and, until now, absence of an effective systemic therapy¹⁰. At diagnosis, 50% of patients present with liver or lung metastases, with a median survival between 4 and 6 months, and 30% of patients presents with a locally advanced tumor with vascular infiltration, having a median survival between 6 and 12 months. Only 15-25% of these tumors are resectable at the time of diagnosis, with this group having a median survival of 20-25 months, a survival at 5 years of 10-25%, and a local recurrence rate during the first 2 years of 75%(11-14). In spite this data, there have been published recently several works indicating that a progressive change is taking place in the prognosis of CP (6,7,15-17). On one side, important advances have been incorporated in the diagnosis and assessment of tumor resectability, as well as in the perioperative management, postoperative complications management and oncologic adjuvant therapy. On the other, initially non-invasive tumors like intraductal papillary neoplasms and mucinous neoplasms have been described, which can undergo surgery in an early stage before transforming into a malignant tumor (18). Despite these improvements, PC still raises certain nihilism. In a study of 192.500 patients with pancreatic cancer, Bilimoria described that less than 40% of patients with early-stage tumors were operated in the United States, and that more than 40% of patients with pancreatic cancer are offered no therapy for the poor general prognosis (19).

These improvements represent an important technological development and resource consumption. A coordinated multidisciplinary approach offers an appropriate study of tumor involvement and an accurate assessment of pancreatic tumors resectability. In this way, unnecessary explorative laparotomies in patients with unresectable diseases can be avoided, saving surgery for those patients with real surgical resection chances (7). In our study, CT and EUS diagnostic accuracy was 91% and 93% respectively, with a radiologic and surgical tumor resectability concordance of 91% (30 of 33 patients), in tune with published studies (4,20).

When handling with resectable tumors, preoperative biliary drainage is still a controversial aspect due to possible increase of local septic complications, but it can be useful for surgical scheduling and for those patients undergoing preoperative neoadjuvant therapy (4). In our study, this procedure was performed on 15 patients and neither local nor systemic sepsis significant differences appeared between patients with biliary drainage and without it.

Some reasons to explain the better prognosis of pancreatic cancer in last years have been the advances in perioperative care, surgical technique, and early detection of complications, resulting in a decrease of the surgical mortality of pancreatotomy from 25% in the late 70s, to less than 5% today (21-24,28). In our series, mortality was 3.3% (one patient). Decrease in postoperative morbidity and mortality, and evidence of high rate of perineural and lymph node infiltration of these tumors (90

and 76.7% respectively in our study), has favoured an increase of surgical and oncologic radicalism with the aim of increasing surgical resectability rate and clear resection margins, in order to decrease local recurrency and tumor systemic progression after surgery (25,29-31). In this higher radicalism context, resection of invaded contiguous organs is becoming more common, resulting in a higher complications rate in these patients, but also in over a 35% of survival at 3 years³². In our group, multi-visceral resections were performed in 12% of cases (4 patients) without a higher morbidity or mortality.

Another area of growing interest is vascular resection in locally advanced tumors. At diagnosis, approximately 30% of patients show tumors invading mesenteric or celiac trunk vessels, which were considered irresectable until recently (33-35). In the last years several publications proved that in the absence of distant disease, resection of the porto-mesenteric vein can be performed with a reasonable morbidity, but with a significant increase survival, to patients undergoing pancreatotomy without vascular resection, but with a significant increase of survival. Therefore, more and more teams are starting to work with vascular resection techniques, thus increasing surgical resectability rate (36-39).

Probably, the most decisive factor to explain this recent increase in survival has been the widespread and systematic use of a multimodal treatment that combines surgical resection with new cytostatic agents and/or radiation therapy (20,28). Based on results of neoadjuvant therapy in rectal cancer⁴¹, in the early 90s several groups started a preoperative neoadjuvant scheme with/without radiotherapy for resectable pancreatic cancer (3,42-46). The main advantages proposed with this new scheme are to provide a complete therapy in most patients, avoiding complex surgery in patients with rapidly progressive disease and/or occult metastases, achieving a complete histological response in 5% of patients, a lower involvement of surgical resection margins, and recently described, obtaining a lower lymph node infiltration rate in the studied specimens, which would mean downstage the tumor (7,46-49). In this line of multimodal therapy, Ohigashi⁵⁰ has recently published the results of a triple therapy with preoperative chemo-radiotherapy, followed by surgery with postoperative years infusion of 5-Fluorouracile through the gastroduodenal artery and superior mesenteric vein, with 5 years survival of 53%, local reoccurrence of 9%, and 7% of hepatic metastasis.

LIMITATIONS OF THE STUDY

The main limitations of this study are the reduced size of the sample and the short follow-up of the patients, resulting from the early stage condition of the program. We expect to be able to incorporate a greater number of patients and to extend the follow-up period to more than 5 years in the future.

CONCLUSIONS

Cure rate in pancreatic cancer is still poor. However, technological development and multidisciplinary approach can improve the accuracy of the tumor extension evaluation, and reduce the number of diagnostic laparotomies without tumor resection. With the application of a multimodal systematic and generalized therapy that combines radical surgery with new schemes of oncologic therapies, surgical resectability and mid and long-term survival seem to be showing a gradual increase. Randomized clinical trials are needed to evaluate the effectiveness of other promising lines such as neoadjuvant therapy, or postoperative intrahepatic infusion of cytostatics.

REFERENCES

- Hidalgo M, Ferrero E, Castillo MJ, Guadarrama FJ, Peláez R, Botella F. Cáncer de páncreas. Epidemiología y diagnóstico. *Rev esp enferm dig* 2004, 96 : 714-22.
- Calvo FA, García Sabrido JL, Calín A. Alternativas terapéuticas en el cáncer de páncreas localmente avanzado (irreseccable). *Oncología* 2004, 27: 205-8.
- White RR, Tyler DS. Neoadjuvant therapy for pancreatic cancer: the Duke experience. *Surg Oncol Clin N Am* 2004. 13: 675-84.
- Alexakis N, Halloran C, Raraty M, Ghaneh P, Sutton R, Neoptolemos JP. Current standards of surgery for pancreatic cancer. *Br J Surg* 2004; 91: 1410-27.
- Figueras J, Codina-Barreras A, López-Ben S, Maroto A, Torres-Bahí S, González HD. Duodenopancreatectomía cefálica en tumores periampulares. Disección de la arteria mesentérica superior como abordaje inicial. Descripción de la técnica y evaluación de nuestra experiencia inicial. *Cir Esp* 2008, 83: 186-93.
- Schnelldorfer T, Ware A, Sarr M, MD, Smyrk T, Zhang L, RI E. Gullerud JH. Donohue. Long-Term Survival After Pancreatoduodenectomy for Pancreatic Adenocarcinoma. Is Cure Possible? *Ann Surg* 2008; 247: 456-62.
- Katz M, Wang h, Fleming J, Sun CC, Hwang RF, Wolff RA, Varadhachary G, Abruzzese JL, et al. Long term survival alter multidisciplinary Management of resected pancreatic Adenocarcinoma. *Ann Surg Oncol* 2009, 16: 836-47.
- Katz M, Pisters P, Evans D, Sun C, Lee J, Fleming J, et al. Borderline resectable pancreatic cancer: the importance of this emergency stage of disease. *J Am Coll Surg* 2008, 206: 833-846.
- Chandrajit P, Tseng J, Sun C, Wang H, Wolff R, Crane C, Hwang R, Vauthey J, Abdalla E, Lee J, Pisters P, Evans D. Impact of resection status on pattern failure and survival after pancreaticoduodenectomy for pancreatic adenocarcinoma. *Ann Surg* 2007, 246: 52-60.
- Erdmann J, Casper HJ, van Eijck, Jeekel J, Standard resection of pancreatic cancer and the chance for cure. *Am J Surg, Suppl* October 2007, 194 (Supl): S104-S109.
- Michalski CW, Weitz J, Büchler MW. Surgery insight: surgical management of pancreatic cancer. *Nat Clin Pract Oncol* 2007; 4: 526-35.
- Riediger H, Makowiec F, Fischer E, Adam U, Hopt UT. Postoperative morbidity and long term survival after pancreaticoduodenectomy with superior mesenterico-portal vein resection. *J Gastrointest Surg* 2006, 10: 1106-15.
- Heinrich S, Pestalozzi B, Weber M, Bauerfeind P, Knut A, Clavie PA. Prospective Phase II Trial of Neoadjuvant Chemotherapy With Gemcitabine and Cisplatin for Resectable Adenocarcinoma of the Pancreatic Head. *J Clin Oncol* 2008, 26: 2526-31.
- Emick DM, Riall TS, Cameron JL, Winter JM, Lillemoe KD, Coleman J, Sauter PK, Yeo CJ: Hospital readmission after pancreaticoduodenectomy. *J Gastrointest Surg* 2006, 9: 1243-53.
- Matsuno S, Egawa S, Unno M. R0 resection for ductal pancreatic cancer. Japanese experience. *Am J Surg* 2007, 194 (Suppl to October): S110-S114.
- Wagner M, Redaelli C, Lietz M, Seiler CA, Friess H, Büchler MW. Curative resection is the single most important factor determining outcome in patients with pancreatic adenocarcinoma. *Br J Surg* 2004, 91: 586-94.
- David M, Lepage C, Jouve JL, Jooste V, Chauvenet M, Faivre J, Bouvier AM. Management and prognosis of pancreatic cancer over a 30 year period. *Br J Cancer* 2009. 101: 215-8.
- Tanaka M, Chari S, Adsay V, Fernández del Castillo C, Falconi M, Shimizu M, Yamaguchi K, Yamao K, Matsuno S. International Consensus Guidelines for management of intraductal papillary mucinous neoplasms and mucinous cystic neoplasms of the pancreas. *Pancreatology* 2006, 6: 17-32.
- Bilimoria KY, Bentrem DJ, Ko CY, Stewart AK, Winchester DP, Talamonti MS. National failure to operate on early stage pancreatic cancer. *Ann Surg* 2007, 246: 173-80.
- Riall T, Nealon W, Goodwin J, Zhang D, Yong-Fang K, Twonsend CM, Freeman JI. Pancreatic cancer in the general population: improvements in survival over the last decade. *J Gastrointest Surg* 2006, 10: 1212-24.
- Iglesias García J, Lariño Noia J, Domínguez Muñoz JE. Endoscopic ultrasound in the diagnosis and staging of pancreatic cancer. *Rev Esp Enferm Dig.* 2009 Sep; 101(9): 631-8.
- Vázquez-Sequeiros E. Endoscopic ultrasonography - an established technique with a brilliant future. *Rev Esp Enferm Dig.* 2009; 101: 595-600.
- Chen E, Prinz R. Long-term survival after pancreatic cancer treatment. *Am J Surg* 2007, 194 (Suppl to October): S127-S130.
- Gerke H, White R, Byrne MF, Stiffler H, Hurwitz HI, Morse MA, Mitchell RM, Branch MS, et al. Complications of pancreaticoduodenectomy after neoadjuvant chemoradiation in patients with and without preoperative biliary drainage. *Digestive and Liver Disease* 2004, 36: 412-8.
- Beger H G, Gansauge F, Schwarz M, Poch B. Pancreatic head resection: the risk for local and systemic complications in 1315 patients – a monoinstitutional experience. *Am J Surg, Suppl* 2007 (Suppl October), 194: S16-S19.
- Cameron JL. One thousand consecutive pancreaticoduodenectomies and beyond: a personal series. *Am J Surg, Suppl* 2007 (Suppl October), 194: S11-S15.
- Yeo C, Cameron JL: Pancreatoduodenectomy with or without distal gastrectomy and extended retroperitoneal lymphadenectomy for periampullary adenocarcinoma. Part 2: randomized controlled trial evaluating survival, morbidity and mortality. *Ann Surg* 2002, 236: 355-68.
- Chang DK, Merrett ND, Biankin AV; NSW Pancreatic Cancer Network. Improving outcomes for operable pancreatic cancer: is access to safer surgery the problem? *J Gastroenterol Hepatol.* 2008; 23 (7 Pt 1): 1036-45.
- Cameron JL, Riall TS, Coleman J, KA Belcher. One thousand consecutive pancreaticoduodenectomies. *Ann Surg* 2006; 244: 10-5.
- Brooks A, Marcus S, Gradek C, Newman E, Shamamian P, Gouge T, Patcher H, Eng K. Decreasing length of stay after pancreaticoduodenectomy. *Arch Surg* 2000, 135: 823-30.
- Müller MW, Friess H, Kleef J, Dahmen R, Wagner M, Hinz U, Breisch-Girbig D, Ceyhan G O, Büchler MW. Is there still a role for total pancreatectomy? *Ann Surg* 2007; 246, 966-75.
- Königer J, Wente MN, Müller-Stich BP, di Mola F, Gutt C, Müller MW, Friess H, Büchler MW. R2 resection in pancreatic cancer: does it make sense? *Langebecks Arch Surg* 2008, 393: 929-34.
- Hernández J, Mullinax J, Clark W, Toomey P, Villalobid D, Morton C, Ross S, Rosemurgy A. Survival after pancreaticoduodenectomy is not improved by extending resections to achieve negative margins. *Ann Surg* 2009, 250: 76-80.
- Hartwig W, Hackert T, Hinz U, Hassenpflug M, Strobel O, Büchler M W, Werner J. Multivisceral Resection for Pancreatic Malignancies. Risk-Analysis and Long-Term Outcome. *Ann Surg* 2009; 250: 81-7.
- Tseng EP, Lee J, Pisters P, Evans D. Venous resection in pancreatic cancer surgery. *Best Practise & Research Clinical Gastroenterology* 2006, 2: 349-64.
- Ramacciato G, Mercantini P, Petrucciani N, Giaccaglia V, Nigri G, Ravaioli M, Cescon M, Cucchetti A, Del Gaudio M. Does portal-superior mesenteric vein invasion still indicate irresectability for pancreatic carcinoma? *Ann Surg Oncol* 2009, 16: 817-25.

37. Hirano S, Kondo S, Hara T, Ambo Y, Tanaka E, Shichinohe T, Suzuki O, Hazama K. Distal pancreatectomy with en block celiac axis resection for locally advanced pancreatic body cancer. *Ann Surg* 2007; 246: 46-51.
38. Yekebas EF, Bogoevski D, Cataldegirmen G, Kunze C, Marx A, Vashist Y, Schurr P, Liebl L, Thielges S, Gawad K, Schneider C, Izbicki J. En block vascular resection for locally advanced pancreatic malignancies infiltrating major blood vessels. *Ann Surg* 2008; 247: 300-9.
39. Gagandeep S, Artinyan A, Jabbour N, Mateo R, Matsuoaka L, Sher L, Geny Y, Selby R. Extended pancreatectomy with resection of the celiac axis: the modified Appleby operation. *Am J Surg* 2006; 192: 330-5.
40. Figueras J, Brox-Jiménez A, López-Ben S, Albiol T, Falguera L. Pancreatectomía distal con resección del tronco celiaco: una buena opción terapéutica para tumores de páncreas localmente avanzados. *Cir Esp* 2009; 85, 1: 54-63.
41. Kondo S, Katoh H, Hirano S, Ambo Y, Tanaka E, Okushiba S, Morikawa T. Results of radical distal pancreatectomy with en block resection of the celiac artery for locally advanced cancer of the pancreatic body. *Langebeck Arch Surg* 2003; 388: 163-6.
42. Bilimoria K, Bentrem D, Ko C, Tomlinson J, Stewart A, Winchester D, Talamonti M. Multimodality therapy for pancreatic cancer in the U.S. *Cancer* 2007; 110: 1227-34.
43. Sauer R, Becker H, Hohenberger W. Preoperative versus postoperative chemoradiotherapy for rectal cancer. *N Engl J Med* 2004; 351: 1731-40.
44. Heinrich S, Schäfer M, Webe A, TF Bhure U, Pestalozzi C, Clavien P. Neoadjuvant Chemotherapy Generates a Significant Tumor Response in Resectable Pancreatic Cancer Without Increasing Morbidity. Results of a Prospective Phase II Trial. *Ann Surg* 2008; 248: 1014-22.
45. Crane CH, Varadhachary G., Pisters P., Evans D. The argument for preoperative, radiographically respectable pancreatic cancer. *Best Practice & Research Clinical Gastroenterology* 2006; 20: 365-82.
46. Takai S, Satoi S, Yanagimoto H, Toyokama H, Takahashi K, Terekawa MD, Araki H, Matsui Y, et al. Neoadjuvant chemoradiation in patients with potentially resectable pancreatic cancer. *Pancreas*. 2008; 36: e26-32
47. Breslin TM, Hess KR, Harbison DB, Jean M, Cleary KR, Dackiw AP, Wolff RA, Lee JE, Pisters PW, Evans DB: Neoadjuvant Chemoradiotherapy for adenocarcinoma of the pancreas. Treatment variables and survival duration. *Ann Surg Oncol* 2001; 8: 123-32.
48. Palmer DH, Stocken DD, Hewitt H, Markham CE, Hassan AB, Johnson PJ, Buckels JAC, Bramhall SR. A randomized phase 2 trial of neoadjuvant chemotherapy in resectable pancreatic cancer. Gemcitabine alone versus gemcitabine combined with cisplatin. *Ann Surg Oncol*. 2007; 14: 2088-96.
49. White RR, Xie HB, Gottfried MR, Czito BG, Hurwitz HI, Morse Ma, Blobe GC, Paulson EK, et al. Significance of histological response to preoperative chemoradiotherapy for pancreatic cancer. *Ann Surg Oncol* 2005; 12 (3): 214-21.
50. Moutardier V, Magnin V, Turrini O, Viret F, Hennekinne-Mucci S, Gonçaves A, Pesenti C, Guiramand J, Lelong B, Giovannini M, Monges G, Houvenaeghel G, Delpero JR. Assessment of pathologic response after preoperative chemoradiotherapy and surgery in pancreatic adenocarcinoma. *Int J Radiation Oncology* 2004; 60: 437-43.
51. Pipas JM, Barth RJ, Zaki B, Tsapakos MJ, Suriawinata AA, Bettmann M, Cates JM, Ripple GH, Sutton GE, et al. Docetaxel/ Gemcitabine followed by Gemcitabine and external beam radiotherapy in patients with pancreatic adenocarcinoma. *Ann Surg Oncol* 2005; 12: 995-1004.
52. Ohigashi H, Ishikawa O, Eguchi H, Takashishi H, Gotoh K, Yamada T, Yano M, Nakaizumi A, Uehara H, Tomita Y, Nishiyama K. Feasibility and efficacy of combination with preoperative full-dose gemcitabine, concurrent three-dimension liver perfusion chemotherapy for T3-pancreatic cancer. *Ann Surg* 2009; 250: 88-95.
53. Espallargues M, Almazán C, Tebé C, Pla R, Pons JM, Sánchez E, Mías M, Alomar S, Borrás JM; Management and outcomes in digestive cancer surgery: design and initial results of a multicenter cohort study. *Rev Esp Enferm Dig*. 2009; 101: 680-96.