

## Endoscopic management of duodenal levodopa-carbidopa therapy of advanced Parkinson's disease

Carmen Garrido Durán<sup>1</sup>, Sam Khorrami Minaei<sup>1</sup>, Pau Sendra Rumbeu<sup>1</sup>, Joaquín Fernández García<sup>1</sup>, Marcelo García Hernández<sup>1</sup> and Inés Legarda Ramírez<sup>2</sup>

<sup>1</sup>Endoscopy Unit. Department of Gastroenterology. Hospital Universitario Son Espases. Palma de Mallorca, Spain. <sup>2</sup>Department of Neurology. Hospital Universitario Son Espases. Palma de Mallorca, Spain

**Received:** 09/04/2019 · **Accepted:** 01/05/2019

**Correspondence:** Carmen Garrido Durán. Department of Gastroenterology. Hospital Universitario Son Espases. Ctra. de Valldemossa, 79. 07010 Palma de Mallorca, Illes Balears. Spain. **e-mail:** mariad.garrido@ssib.es

### ABSTRACT

**Background:** treatment of intraduodenal levodopa using percutaneous endoscopic gastrostomy is an alternative therapy in patients with advanced Parkinson's disease. There are few studies that have evaluated the endoscopic aspects of this technique.

**Objectives:** to describe our experience and adverse events regarding this technique in advanced Parkinson's disease.

**Method:** a retrospective study was performed from January 2007 to January 2019 in a tertiary healthcare center.

**Results:** thirty-seven patients aged  $65.1 \pm 10.3$  years were included in the study, 21 were male and the disease duration was ten years (1-26). The median follow-up was 16 months (1-144). The device was successfully placed in all cases. The persistence rate with the PEG-D at the end of follow-up was 62.2%. The system was removed in 14 patients, seven due to neurological impairment, four because of the decision of the patient and three due to related events. Fifty-nine adverse events occurred in 23 patients (62.2%, 0.63 per patient-year), four of which were severe (8.1%, 0.05 per patient-year). Minor adverse events included 14 (37.8%) related to the stoma, six (16.2%) to the gastric tube and 15 (40.5%) to the duodenal tube. Forty-four system replacements were performed in 20 patients (54.1%, 0.52 per patient-year). Male sex, age over 70 and a higher comorbidity index were associated with a greater likelihood of persistence of the system (OR: 0.14, 95% CI: 0.03-0.62; OR: 0.52, 95% CI: 0.32-0.86; OR: 0.16, 95% CI: 0.03-0.99, respectively). No predictors of adverse events associated with PEG-D were identified.

**Conclusions:** percutaneous endoscopic gastrostomy for the continuous delivery of duodenal levodopa is a highly effective technique. Adverse events are common, although most are resolved by endoscopy.

**Key words:** Parkinson's disease. Levodopa. Percutaneous endoscopic gastrostomy. Continuous enteral infusion.

### INTRODUCTION

Parkinson's disease (PD) is a neurodegenerative disorder and the treatment of choice is levodopa. Complications such as fluctuations and dyskinesias are related to plasma fluctuations of dopaminergic drugs and are frequent and difficult to control. When patients reach this phase of the disease, second-line therapies are proposed. Deep brain stimulation of the subthalamic nucleus is the main surgical alternative to conventional treatment. Treatment with a Duodopa<sup>®</sup> (levodopa-carbidopa gel for intraduodenal infusion) by a duodenal tube (DT) inserted through a percutaneous endoscopic gastrostomy (PEG) is also a suitable alternative to surgical treatment. Continuous infusion of the drug through a portable pump in the duodenum enables a more controlled absorption and distribution of the drug. Furthermore, this ensures more stable plasma levels of levodopa and continuous dopaminergic stimulation, which reduces motor fluctuations and dyskinesias. The role of the endoscopist is essential in the placement of the gastrostomy with the duodenal extension tube (PEG-D) and the treatment of complications derived from the system.

The main objective of this study was to describe our experience in the placement and management of complications in patients with advanced PD that underwent treatment with the Duodopa<sup>®</sup> in a tertiary healthcare center. In addition, factors associated with the persistence of the system, the appearance of complications and the need for system exchange were also evaluated.

Garrido Durán C, Khorrami Minaei S, Sendra Rumbeu P, Fernández García J, García Hernández M, Legarda Ramírez I. Endoscopic management of duodenal levodopa-carbidopa therapy of advanced Parkinson's disease. *Rev Esp Enferm Dig* 2019; 111(11):828-832

**DOI:** 10.17235/reed.2019.6311/2019

## METHODS

A retrospective observational study was performed in patients with advanced and long-term PD, with a PEG-D fitted for treatment with the Duodopa® between January 2007 and January 2019.

Technical success was defined as the correct placement of the PEG-D and persistence was defined as maintenance of the device until the end of follow-up or death not related to the technique. Severe complications included hemorrhage, perforation, peritonitis, aspiration, necrotizing fasciitis or death related to the technique. Whereas minor complications were subdivided as related to the stoma (infections, granulomas), related to the PEG (buried bumper syndrome, post-gastrostomy abdominal pain, asymptomatic pneumoperitoneum) or related to the tube (migration, knotting, obstruction, bezoar, jejunitis, or duodenal ulcer by decubitus). The Charlson Comorbidity Index was used to evaluate the impact of comorbidity (1).

### Protocol and endoscopic procedure

Expert neurologists in PD and clinicians responsible for the monographic consultation of Movement Disorders selected candidates for treatment. Patients were admitted three days before the placement of the PEG-D. The departments of Gastroenterology and Neurology coordinated to perform the prior test of Duodopa® by a nasoduodenal tube connected to a portable pump, in order to adjust the dose, assess the effectiveness of the drug and rule out side effects. Once the suitability of the candidate was evaluated, the PEG-D was placed during a single procedure. All patients provided informed consent to undergo the technique. Coagulation tests were performed and systemic antibiotic prophylaxis was administered with ceftazidime 2 g for 1-2 hours before the technique. All procedures were performed by two experienced endoscopists and all patients underwent deep sedation with propofol without endotracheal intubation. PEGs (Freka system of 15F, Abbvie™) with duodenal extension (Freka intestinal tube of 9F, Abbvie™) were used for the continuous infusion of Duodopa®.

A conventional gastroscope (Olympus GIF-H190) was used to insert the system using the pull-push method. Once the gastric access guided by transillumination was performed, the duodenal tube was inserted through the PEG and was positioned with a foreign body clamp to the second-third duodenal portion. Finally, the duodenal tube was connected to a portable infusion pump that infuses medication into the intestine. Radiological controls were not performed when the patient did not present any complication or symptom immediately after the procedure. The correct functioning of the infusion pump confirmed the proper positioning of the probe. In the absence of complications, feeding was restarted 24 hours after the procedure.

Members of the Spanish Parkinson Federation instructed the patients and their relatives or direct caregivers in the care and hygiene of the PEG and the management of the infusion pump. Weekly and monthly check-ups were performed in a nurse consultation for stoma control. A telephone contact was provided in order to ask any questions or inform about any problems. Systems were replaced every 24 months, or earlier in the case of complications.

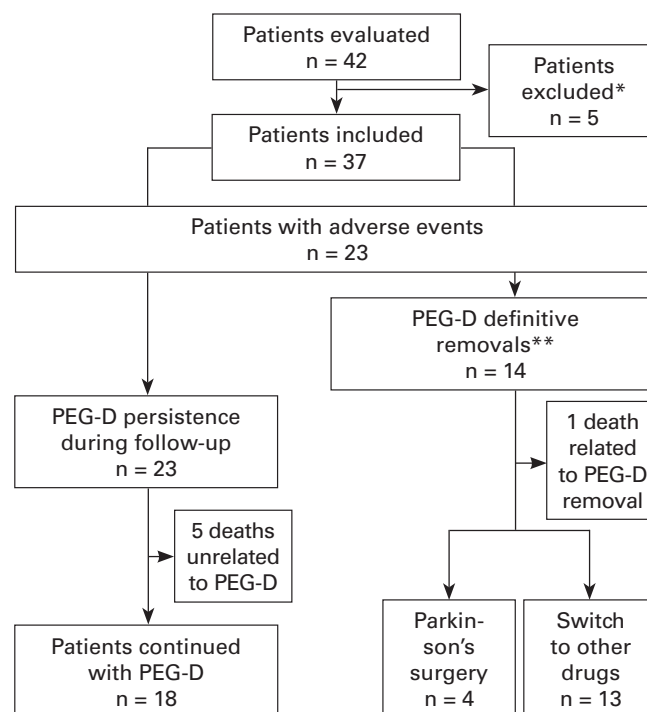
### Statistical analysis

Continuous variables are expressed as the mean and standard deviation or the median and the range and qualitative variables are expressed as percentages. The incidence of complications and system changes are described in the patient-year follow-up form. Qualitative variables were compared using the Chi-square test or Fisher's exact test. Comparisons between continuous variables were made using the nonparametric Wilcoxon test. The Kaplan-Meier method was used to evaluate the effect of the variables over time. In addition, a multivariate analysis was performed using the Cox logistic regression to evaluate the factors identified by the univariate analysis. A p value less than 0.05 was considered as statistically significant.

## RESULTS

Forty-two patients with advanced and long-term PD were evaluated to start treatment with Duodopa® between January 2007 and January 2019. One patient refused the placement of a PEG and four had a poor response to the nasogastric tube test. Therefore, 37 patients were finally included (Fig. 1).

The baseline characteristics of patients are summarized in table 1. Most of the patients were male with a long-standing PD and were polymedicated with more than four drugs. The PEG-D was successfully placed in all cases. Thirty-six procedures were performed by the conventional endoscopic route and one by a laparoscopic-assisted endoscopic route in an overweight patient due to the absence of transillumination to locate the puncture site of the PEG. Patients were followed-up for a median of 16 (1-144) months.



**Fig. 1.** Flowchart of study population (\*4 cases of a lack of response to nasoenteral levodopa infusion, 1 death prior to PEG-D insertion. \*\*7 cases of cognitive impairment, 4 patient decisions and 3 PEG-D adverse events).

**Table 1.** Baseline characteristics of patients

Demographics	n = 37
Age (years) mean ± SD	65.1 ± 10.3
Male sex, n (%)	21 (56.8)
PD duration (years), median (range)	10 (25)
Comorbidity*, median (range)	3 (7)
Previous PD surgery, n (%)	9 (24.3)
Polymedication (> 4 drugs), n (%)	36 (97.3)

\*Charlson comorbidity index. PD: Parkinson's disease.

The persistence rate with treatment through the PEG-D at the end of follow-up was 62.2%. The PEG-D was withdrawn in 14 patients (37.8%), seven due to clinical worsening (decreased neurological response), four due to patient decision and three due to complications. Follow-up of two patients was lost due to the fact that they moved to another location and seven patients died during follow-up due to causes that were not related to the technique.

A total of 53 complications occurred in 23 patients (62.2%). The incidence of complications associated with PEG-D was 0.63 per patient-year. Three patients (8.1%) suffered major complications related to the PEG-D technique and system. The incidence of major complications in the series was 0.05 per patient-year. A 59-year-old patient suffered a bronchoaspiration during PEG-D removal and died a few days later. Another 68-year-old male patient suffered acute abdominal pain three months after the last PEG-D replacement. Pneumoperitoneum and diffusely distributed free fluid were observed on the abdominal computed tomography (CT), as well as air bubbles at the level of the Treitz angle, suggestive of intestinal perforation. The patient underwent surgery, which confirmed several small perforations in the proximal jejunum secondary to decubitus of the DT that were subsequently removed via a resection of 15 cm of the jejunum. Two weeks later, a new DT was placed to restart the duodenal infusion of levodopa and no other complications were observed until the end of the follow-up. Finally, a 74-year-old patient presented an upper gastrointestinal bleed and progressive anemization 15 months after the placement of the PEG-D. Gastroscopy confirmed the presence of an inner-tube induced second duodenal portion decubitus ulcer. The DT was removed and the patient developed favorably and was able to have a new one replaced four weeks later. Minor complications were more frequent and are summarized in table 2. All were resolved with medical treatment and/or endoscopic management.

Forty-four probe replacements were performed in 20 of the 37 patients (54.1%, 0.52 per patient-year), mostly due to minor complications of the PEG-D. The median time from placement of the PEG-D until the first replacement was 14 months (range 39).

Male sex, age over 70 and a higher comorbidity index were associated with a higher likelihood of preserving the PEG-D (OR: 0.14, 95% CI: 0.03-0.62; OR: 0.52, 95% CI: 0.32-0.86; OR: 0.16, 95% CI: 0.03-0.99, respectively). However, no predictive factors were identified associated with the appearance

**Table 2.** Complications

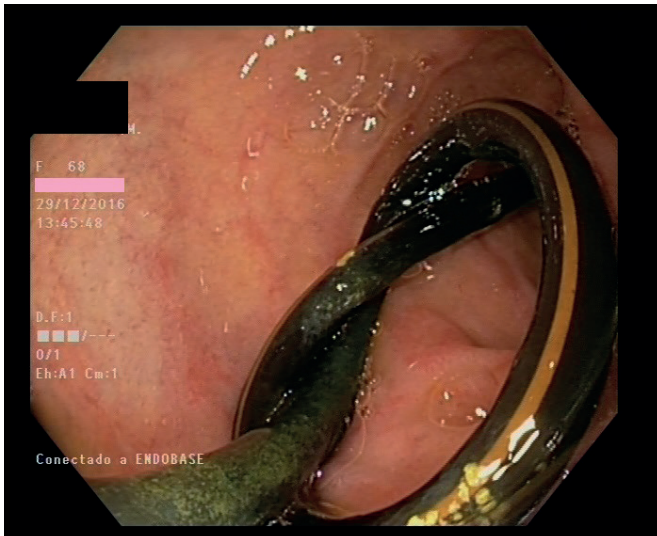<b>Severe complications, no. patients/total (%)</b>	<b>3/37 (8.1)</b>
Hemorrhage	1
Perforation	1
Bronchoaspiration	1
Fasciitis	0
Death	1
<b>Minor complications</b>	
<b>Related to stoma, no. patients/total (%)</b>	<b>14/37 (37.8%)</b>
Wound infection	12
Granulomas	5
<b>Related to PEG, no. patients/total (%)</b>	<b>6/37 (16.2%)</b>
Buried bumper syndrome	2
Abdominal pain	2
Pneumoperitoneum	4
<b>Related to inner tube, no. patients/total (%)</b>	<b>15/37 (40.5%)</b>
Migration	7
Knotting	6
Obstruction	3
Jejunitis	1
Duodenal ulcer	5
Bezoar	2

of complications related to PEG-D or the need for system replacement.

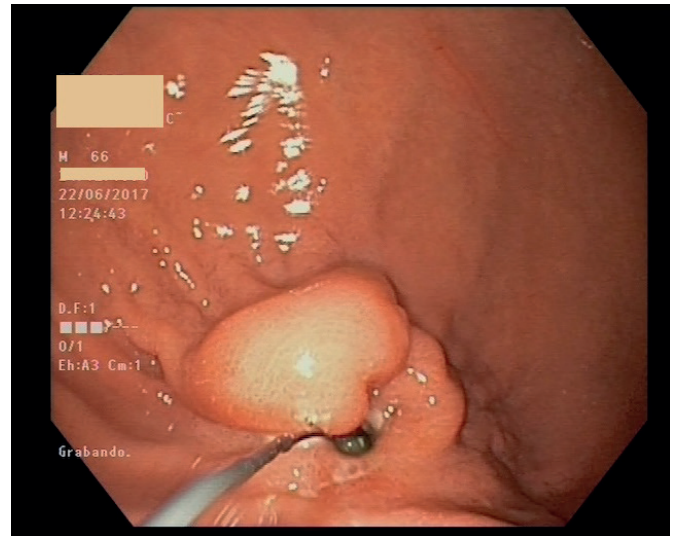
## DISCUSSION

Continuous enteral infusion of levodopa-carbidopa is a therapeutic alternative for patients with PD who suffer from motor fluctuations that do not improve with oral medication (2-4). This therapy is easily accessible, reversible and can be proposed prior to the surgical treatment of PD or as an alternative in patients with surgical exclusion criteria. The first results in patients with PD treated with intraduodenal levodopa date from 1993 (5). In 2004, Solvay Pharma obtained the indication for the use of the drug in patients with PD in several European countries. In Spain, it was approved in 2006 for patients with advanced PD with severe motor fluctuations not controlled with oral medication (6). Experience with this treatment in Europe has progressively increased in recent years and the results have been widely described from the point of view of the neurological response (4-9). However, there is no information currently available about the results and complications of the technique from an endoscopic point of view. There are only a few series of cases with a limited number of patients in the literature (10-14).

In our experience, endoscopic placement of the system offers a high technical success and a low rate of major complications. According to other series (14), minor complications are common and require that the patient undergo endoscopic or radiological procedures that can sometimes



**Fig. 2.** Duodenal probe tying.



**Fig. 3.** Buried bumper syndrome.

condition the maintenance of the system despite neurological improvement.

Local wound infection and granuloma formation were the most frequent minor complications in our series, which is in accordance with other publications (2,8,15,16). Preventive measures to avoid this are systemic antibiotic prophylaxis with amoxicillin clavulanic or a cephalosporin (17) that is given before the procedure as well as performing a large incision that exceeds the PEG tube by about 2 mm. In addition, washing with soap and water (drying and applying an antiseptic solution) on a daily basis, keeping the stoma uncovered, applying moisturizing solutions, changing the location of the pump to avoid that the tube rubs on the same area of the stoma and daily gentle mobilizations of the external probe are recommended.

The second most frequent complication was migration or dislocation of the internal tube that forced its replacement or endoscopic repositioning. In other series, this occurred in up to 38% of cases (15). This is usually due to the malposition of the connections, inadequate insertion of the catheter in the duodenum or accidental traction due to sudden movements related to the neurological disease, especially in patients with an associated cognitive impairment. Treatment consists of repositioning or replacement of the tube endoscopically (12).

Two cases of buried bumper syndrome occurred 13 and 41 months after PEG placement. This is a rare complication of gastrostomy in which the inner stop plate becomes covered with gastric mucosa. Different endoscopic techniques have been described for its release, for example the use of an endoscopic incision with needle electrocautery. This has also been described in other series with PEG-D (18,19).

Asymptomatic pneumoperitoneum occurs in up to 50% of cases and is due to endoscopic air insufflation associated with the puncture of abdominal and gastric walls. It usually resolves spontaneously, thus the management is conservative in the absence of clinical data of peritonitis. The incidence of pneumoperitoneum decreases significantly with carbon dioxide insufflation compared to the use of ambient air and there are no differences in abdominal circumfer-

ence or abdominal distension (14.3 vs 53.3%) (20-22). In our study, all cases resolved spontaneously.

Tying and the formation of phytobezoars at the distal end of the DT are associated with cases of intestinal hypomotility, which can cause abdominal pain due to aggressive peristalsis (23). In our series, two patients presented phytobezoars and 8 DT knots were detected. It is important to emphasize that the abdominal CT scan did not detect the presence of a bezoar or knotting. Thus, we recommend to endoscopically review the status and position of the DT in patients with acute abdominal pain, once other pathologies have been ruled out. Even in patients with a normal abdominal CT. As in our series, cases of jejunitis secondary to the duodenal probe have also been described (24).

In our study, only one patient, with a jejunal perforation in relation to decubitus by DT that occurred three months after the last replacement, required surgical treatment. The tube was replaced once resolved in this case. All other complications were resolved with medical or endoscopic treatment.

Despite the appearance of complications, preservation of the treatment at the end of follow-up was high (62.2%). Interestingly, more probes were removed in females compared to males. A more advanced age and above all, a greater comorbidity were associated with a greater persistence with the PEG-D. This is probably due to the limited surgical alternative as a treatment for PD.

In our series, no predictors of complications associated with the PEG-D were identified. Cheron et al. did observe an increased risk for the occurrence of complications in patients with a greater comorbidity. However, they did not observe an increased risk of complications in older patients (14).

Although the fact that it is a retrospective study and the number of patients constitutes a limitation, the description of our experience is one of the largest described from the endoscopist point of view after an extensive review of the literature. This may be useful for gastroenterologists or endoscopists starting out in the management of these patients.

In conclusion, our results confirm that the endoscopic placement of a PEG-D for treatment with the Duodopa® in patients with advanced PD achieves a high technical success and is safe. Although complications are common, most are minor and can be resolved endoscopically. To minimize the appearance of complications as much as possible, adequate information and education in the management of the system for patients and caregivers is required. Furthermore, follow-up of these patients in centers with experience in their management is also recommended.

## REFERENCES

- Charlson ME, Pompei P, Ales KL, et al. A new method of classifying prognostic comorbidity in longitudinal studies: development and validation. *J Chronic Dis* 1987;40(5):373-83. DOI: 10.1016/0021-9681(87)90171-8
- Olanow CW, Kieburtz K, Odin P, et al. Continuous intrajejunal infusion of levodopa-carbidopa intestinal gel for patients with advanced Parkinson's disease: a randomised, controlled, double-blind, double-dummy study. *Lancet Neurol* 2014;13(2):141-9. DOI: 10.1016/S1474-4422(13)70293-X
- Nyholm D. Duodopa treatment for advanced Parkinson disease: a review of efficacy and safety. *Parkinsonism Relat Disord* 2012;(18):916-29.
- Buongiorno M, Antonelli F, Cámara A, et al. Long-term response to continuous duodenal infusion of levodopa/carbidopa gel in patients with advanced Parkinson disease: The Barcelona registry. *Parkinsonism Relat Disord* 2015;21(8):871-6. DOI: 10.1016/j.parkrelidis.2015.05.014
- Bredberg E, Nilsson D, Johansson K, et al. Intraduodenal infusion of a water-based levodopa dispersion for optimization of the therapeutic effect in severe Parkinson's disease. *Eur J Clin Pharmacol* 1993;45(2):117-22. DOI: 10.1007/BF00315491
- Yáñez Baña RM. Infusión de Duodopa en la enfermedad de Parkinson. *Rev Esp Trast Mov* 2007;7:21-5.
- Santos-García D, Macías M, Llana M, et al. Experiencia con la infusión continua con levodopa intraduodenal (Duodopa) en pacientes con enfermedad de Parkinson avanzada en un hospital de segundo nivel asistencial. *Neurología* 2010;25(9):536-43. DOI: 10.1016/j.nrl.2010.07.018
- Fernández HH, Vanagunas A, Odin P, et al. Levodopa-carbidopa intestinal gel in advanced Parkinson's disease open-label study: interim results. *Parkinsonism Relat Disord* 2013;19(3):339-45. DOI: 10.1016/j.parkrelidis.2012.11.020
- Zibetti M, Merola A, Ricchi V, et al. Long-term duodenal levodopa infusion in Parkinson's disease: a 3-year motor and cognitive follow-up study. *J Neurol* 2013;260(1):105-14. DOI: 10.1007/s00415-012-6597-0
- Negreaunu L, Popescu BO, Babiuc RD, et al. Duodopa infusion treatment: a point of view from the gastroenterologist. *J Gastrointest Liver Dis* 2011;20(3):325-7.
- Dam-Larsen S, Darkahi B, Glad A, et al. Best practice in placement of percutaneous endoscopic gastrostomy with jejunal extension tube for continuous infusion of levodopa carbidopa intestinal gel in the treatment of selected patients with Parkinson's disease in the Nordic region. *Scand J Gastroenterol* 2015;50(12):1500-7. DOI: 10.3109/00365521.2015.1055793
- Santos-García D, De Deus T, López-Pazos E, et al. Manejo de las complicaciones relacionadas con la infusión intraduodenal de levodopa/carbidopa en pacientes con enfermedad de Parkinson. *Rev Neurol* 2014;58:505-15. DOI: 10.33588/rn.5811.2014067
- Klosterman F, Jugel C, Bömelburg M, et al. Severe gastrointestinal complications in patients with levodopa/carbidopa intestinal gel infusion. *Mov Disord* 2012;27(13):1704-6. DOI: 10.1002/mds.25238
- Cheron J, Deviere J, Supiot F, et al. The use of enteral access for continuous delivery of levodopa-carbidopa in patients with advanced Parkinson's disease. *United European Gastroenterol J* 2017;5(1):60-8. DOI: 10.1177/2050640616650804
- Udd M, Lyytinen J, Eerola-Rautio J, et al. Problems related to levodopa-carbidopa intestinal gel treatment in advanced Parkinson's disease. *Brain Behav* 2017;7(7):e00737.
- Devos D, French DUODOPA Study Group (2009). Patient profile, indications, efficacy and safety of duodenal levodopa infusion in advanced Parkinson's disease. *Mov Disord* 2009;24(7):993-1000.
- Jafri NS, Mahidà SS, Minor KS, et al. Meta-analysis: antibiotic prophylaxis to prevent peristomal infection following percutaneous endoscopic gastrostomy. *Aliment Pharmacol Ther* 2007;25(6):647-56. DOI: 10.1111/j.1365-2036.2007.03247.x
- Magaz Martínez M, Martínez Porras JL, López Gómez M, et al. Endoscopic alternative to buried bumper syndrome secondary to Duodopa® pump treatment. *Gastroenterol Hepatol* 2017;40(5):360-2. DOI: 10.1016/j.gastrohep.2016.04.006
- El AZ, Arvanitakis M, Ballarin A, et al. Buried bumper syndrome: low incidence and safe endoscopic management. *Acta Gastroenterol Belg* 2011;74(2):312-6.
- Güvenç BH, Rasa K, Güvenç S. The presence of percutaneous endoscopic gastrostomy (PEG)-related postprocedural pneumoperitoneum. *Endoscopy* 2009;41(Suppl 2):E269-70.
- Murphy CJ, Adler DG, Cox K, et al. Insufflation with carbon dioxide reduces pneumoperitoneum after percutaneous endoscopic gastrostomy (PEG): a randomized controlled trial. *Endosc Int Open* 2016;4(3):E292-5.
- Nishiwaki S, Araki H, Hayashi M, et al. Inhibitory effects of carbon dioxide insufflation on pneumoperitoneum and bowel distension after percutaneous endoscopic gastrostomy. *World J Gastroenterol* 2012;18(27):3565-70. DOI: 10.3748/wjg.v18.i27.3565
- Del-Hoyo-Francisco J, Bustamante-Balen M, Martínez-Torres I, et al. Knotting of Duodopa® duodenal infusion system. *Rev Esp Enferm Dig* 2015;107(5):323-4.
- Magaz Martínez M, Martínez Porras JL, Oliva B, et al. Yeyunitis secundaria a sonda de Duodopa, una complicación diferente. *Rev Esp Enferm Dig* 2016;108(12):815-6.